

NEW YORK CARTILAGE REPAIR SOCIETY

CASE



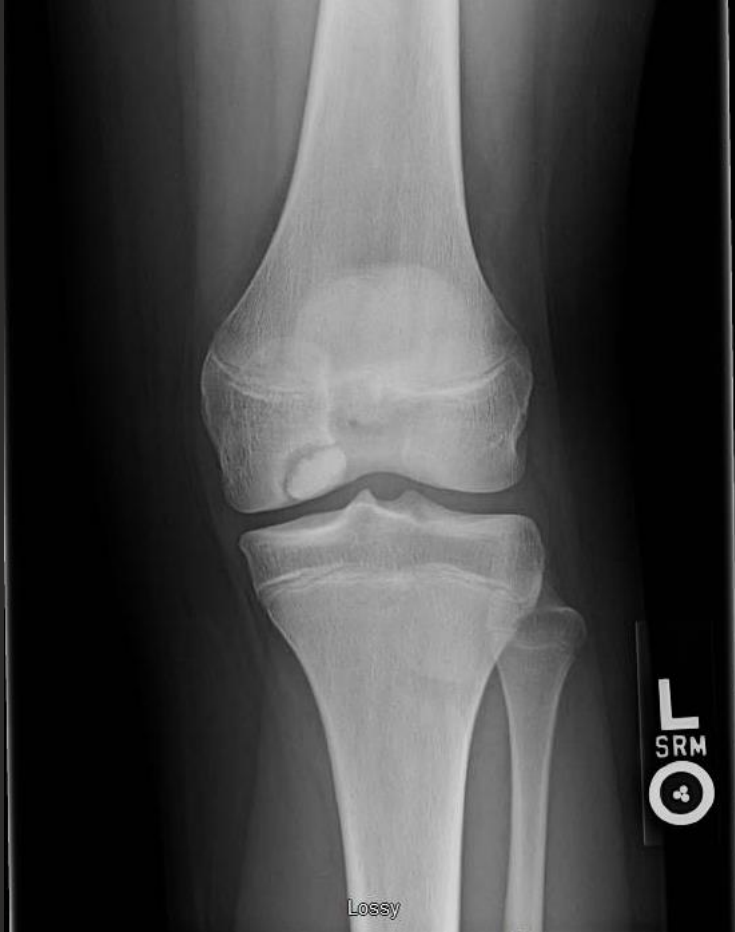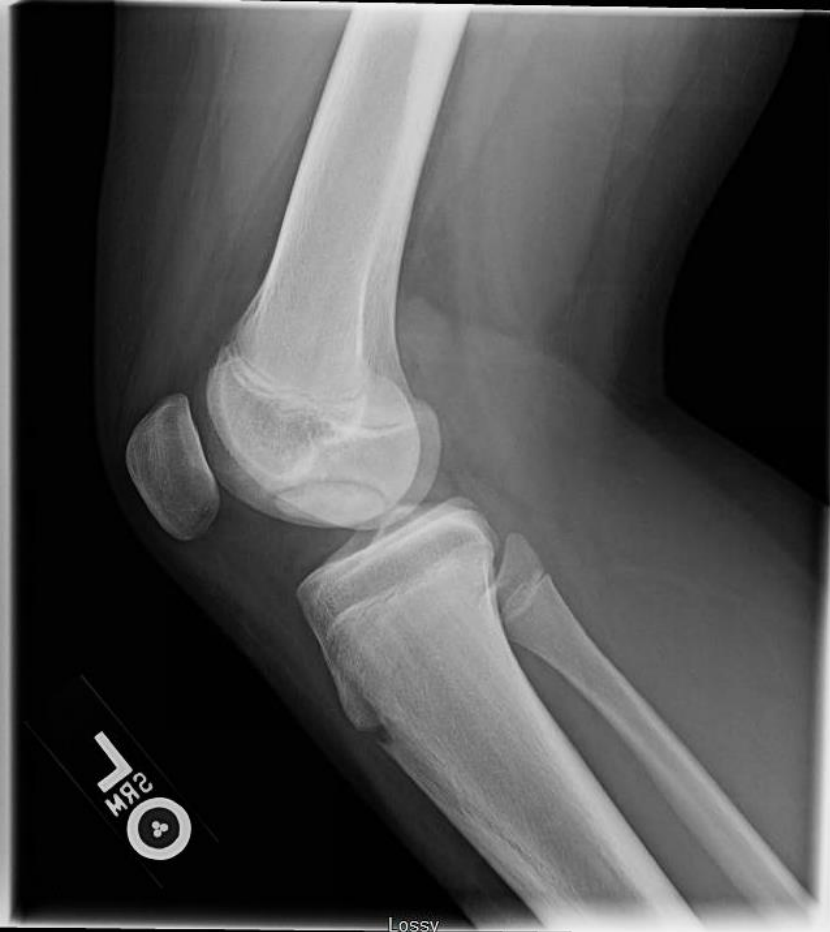Case KM



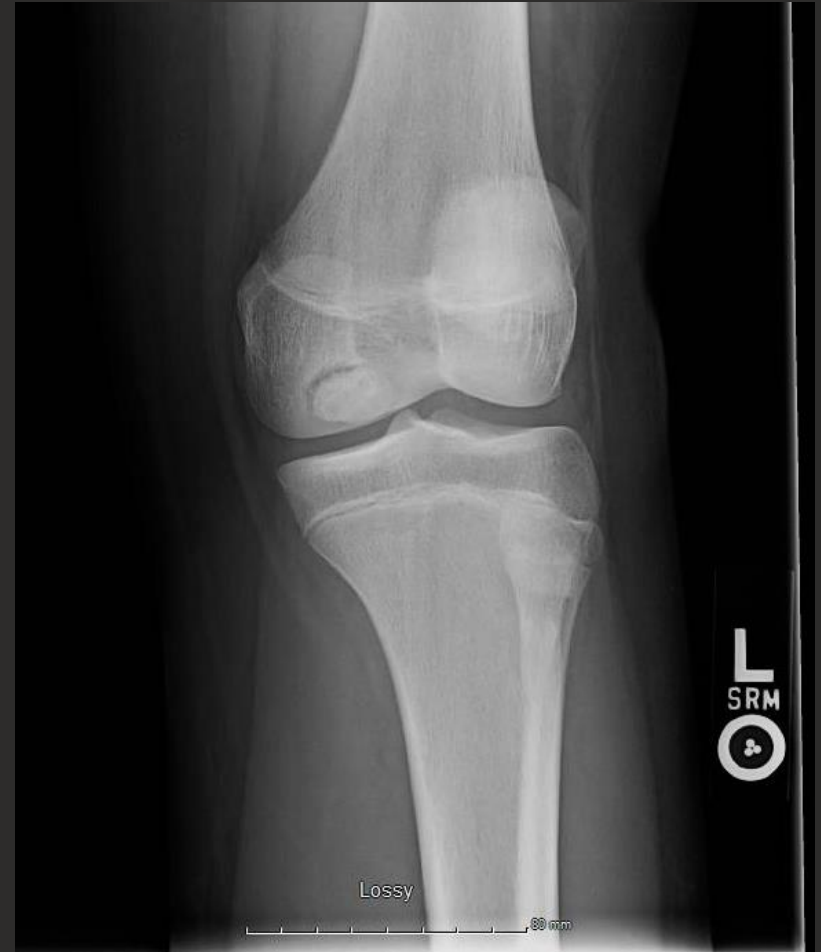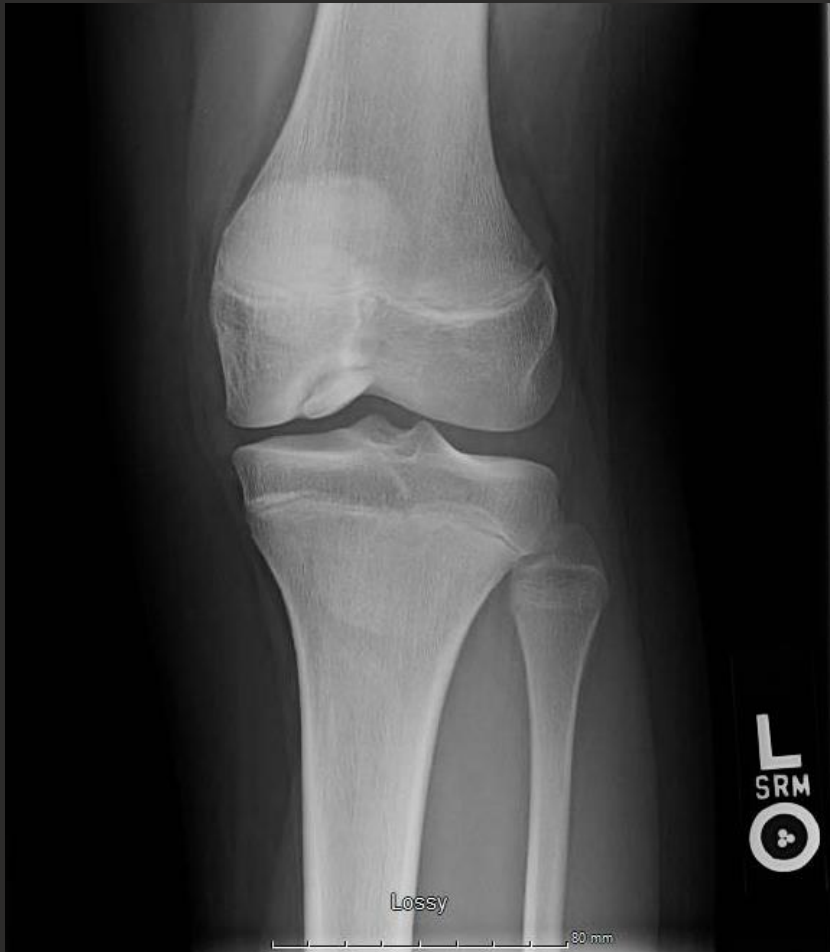KM

- **15 yo female high school basketball player developed left knee pain, swelling and mechanical symptoms in February 2018**
- **Evaluated by local orthopedic surgeon**

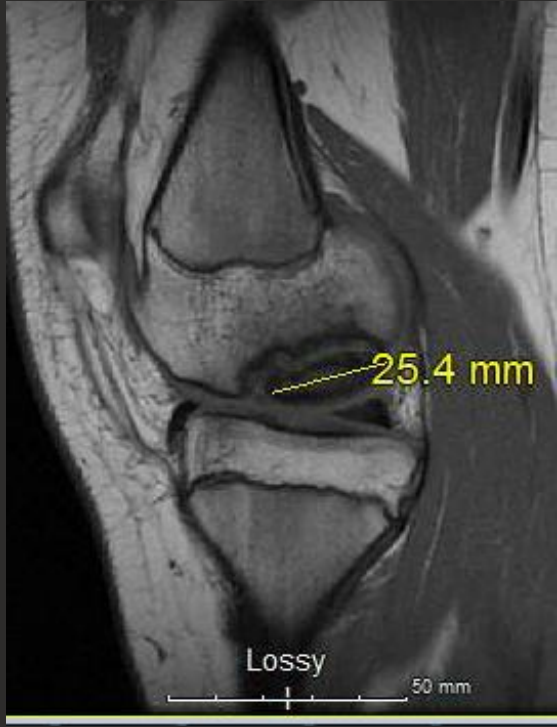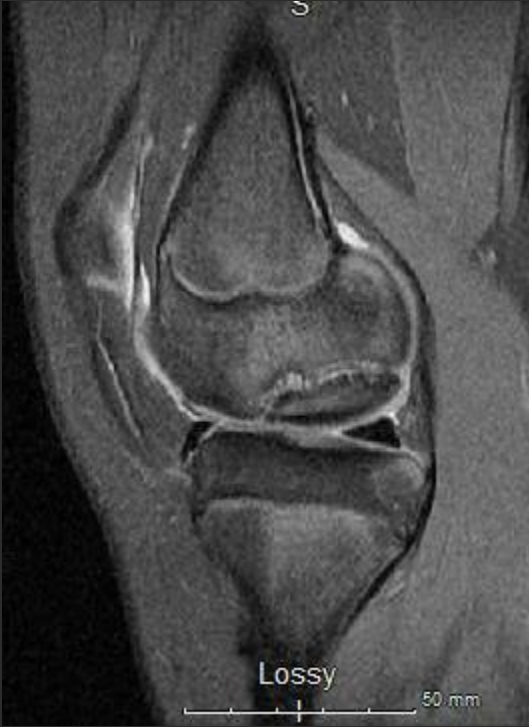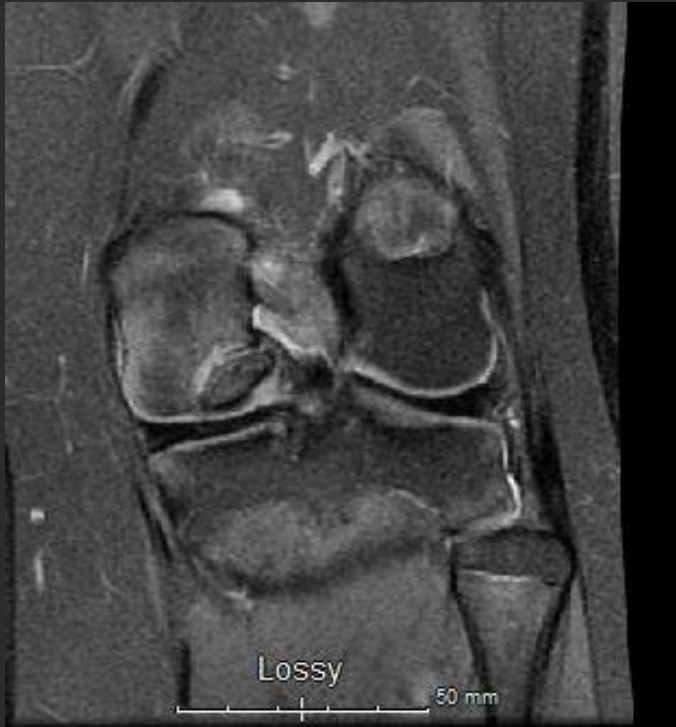2/19/18



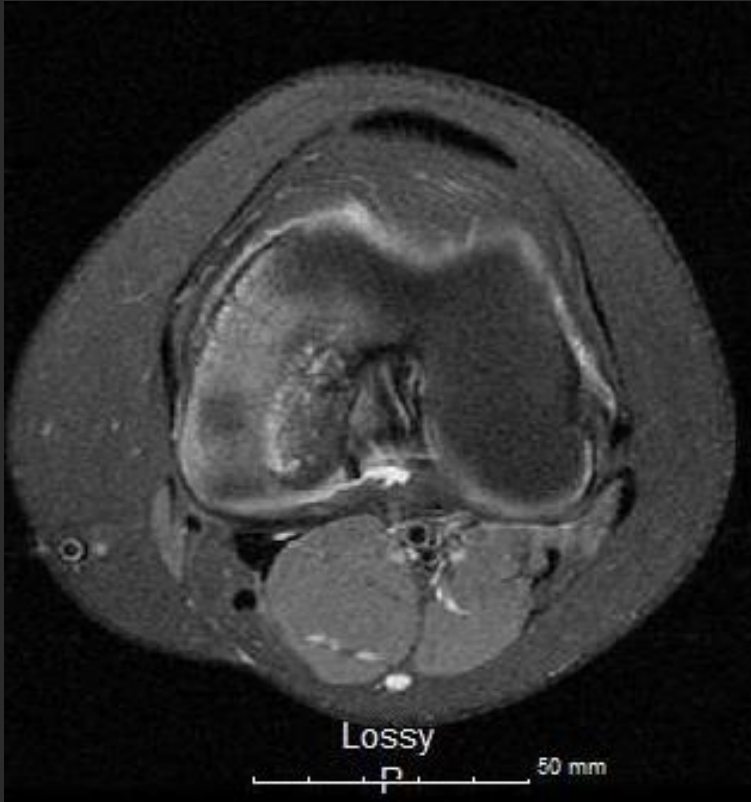
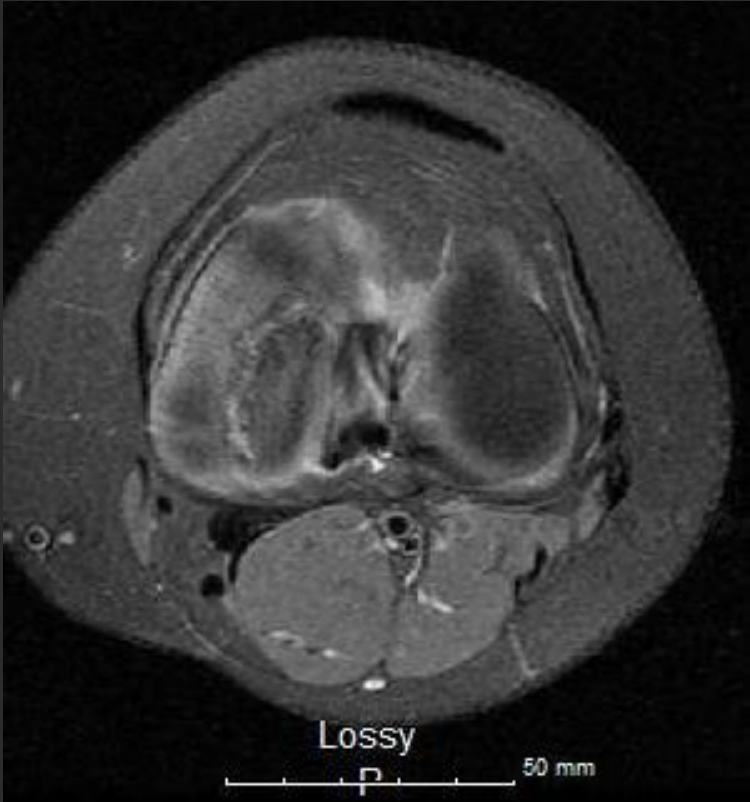
2/19/18



3/10/18



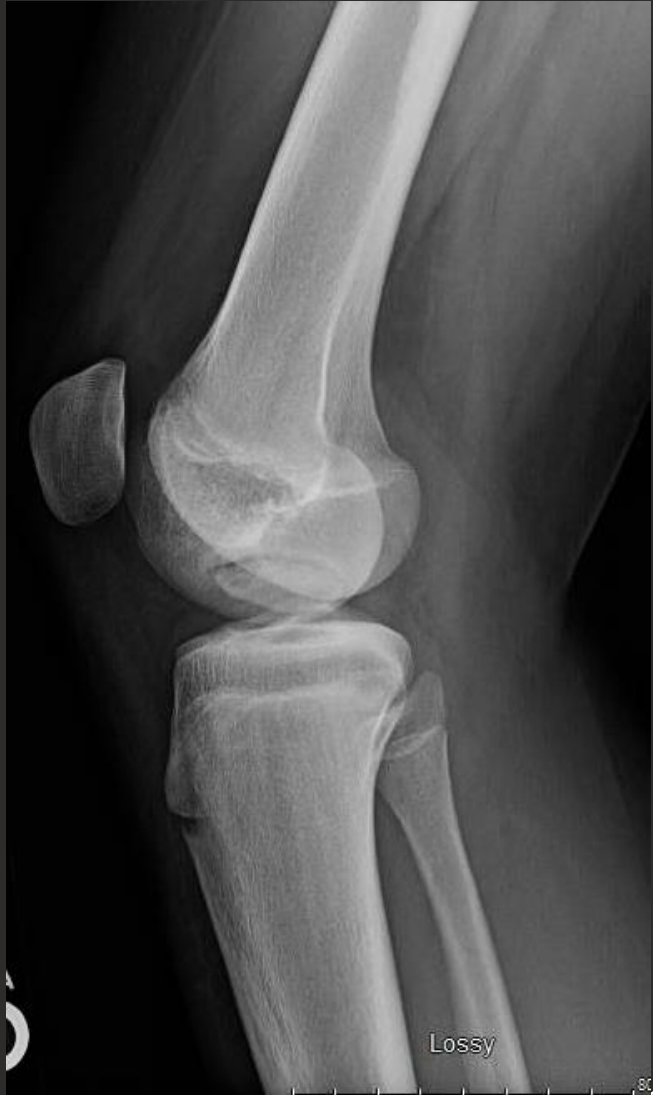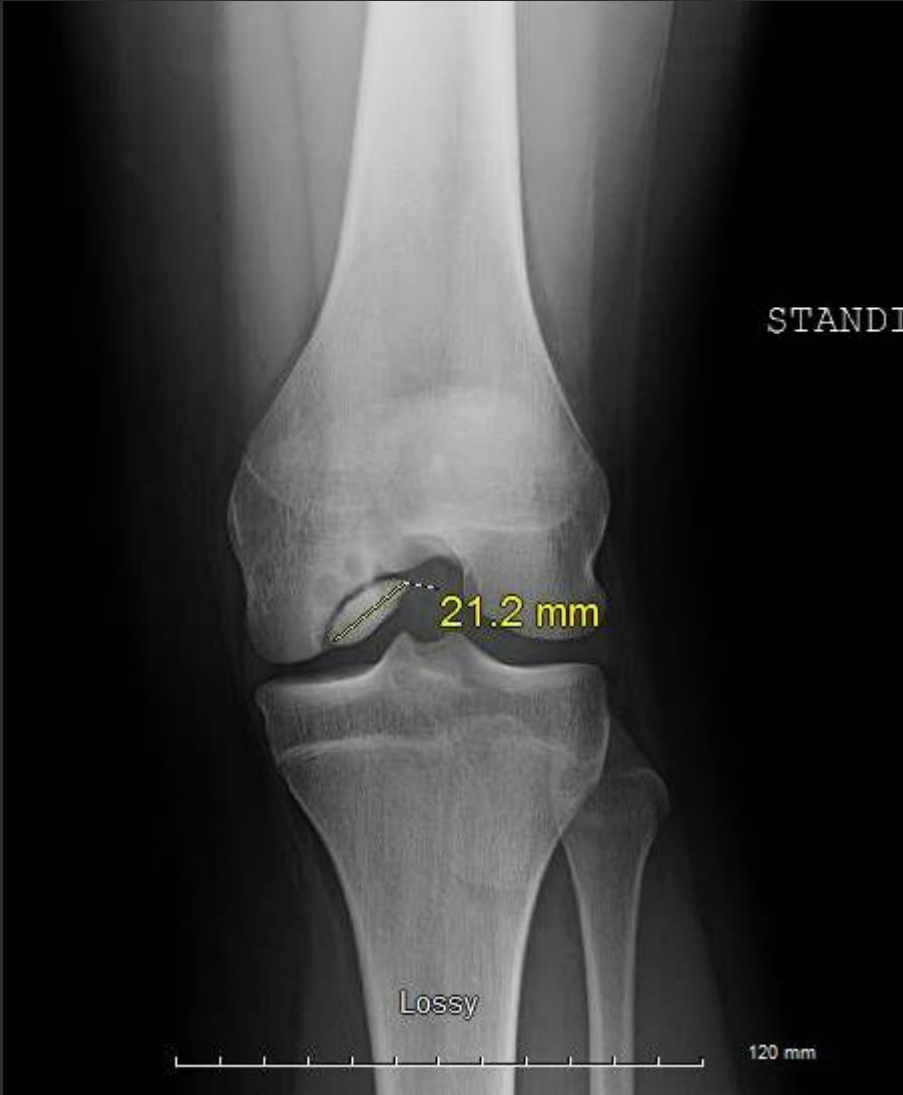3/10/18



History

- Treated nonoperatively with crutches/restricted weightbearing x 3 months
- PT for ROM/strengthening

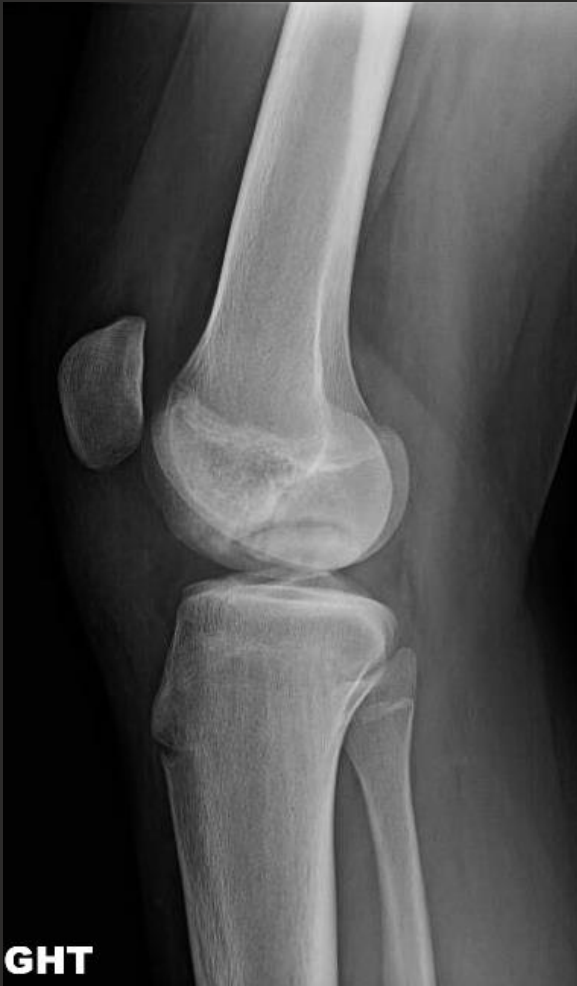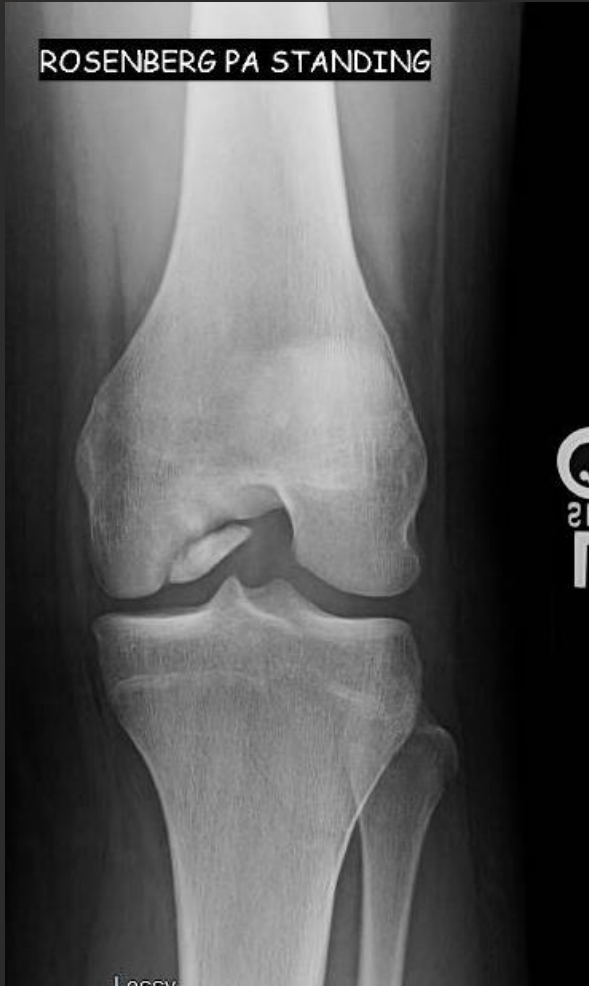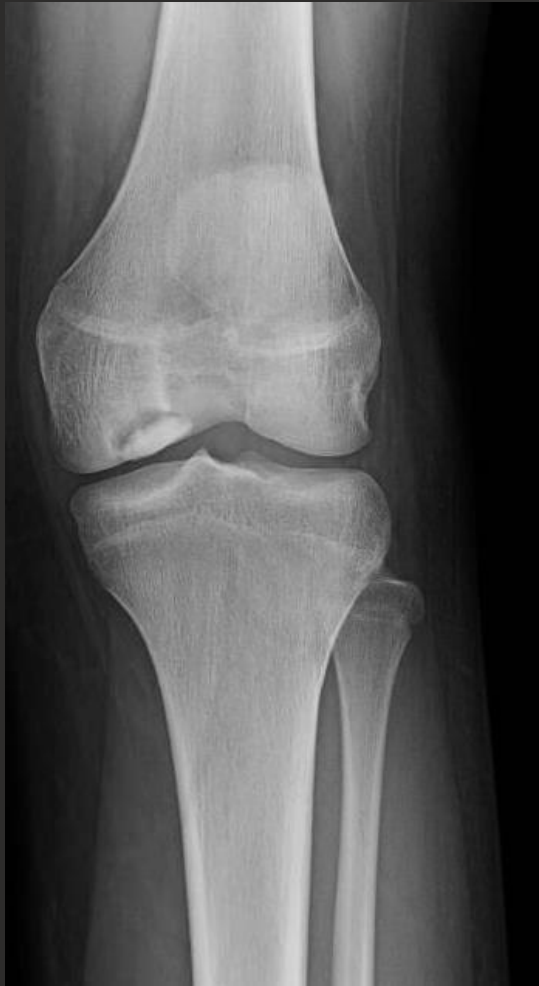9/13/18



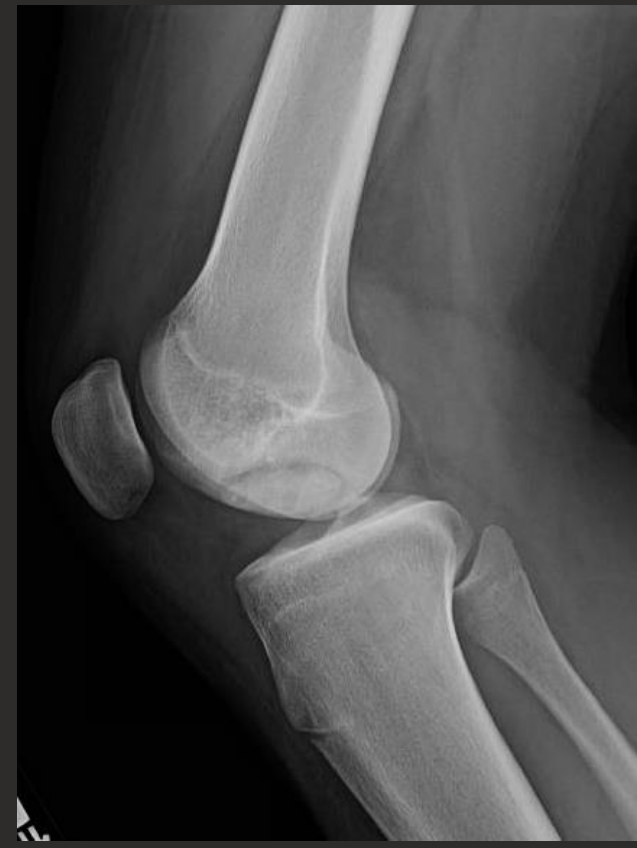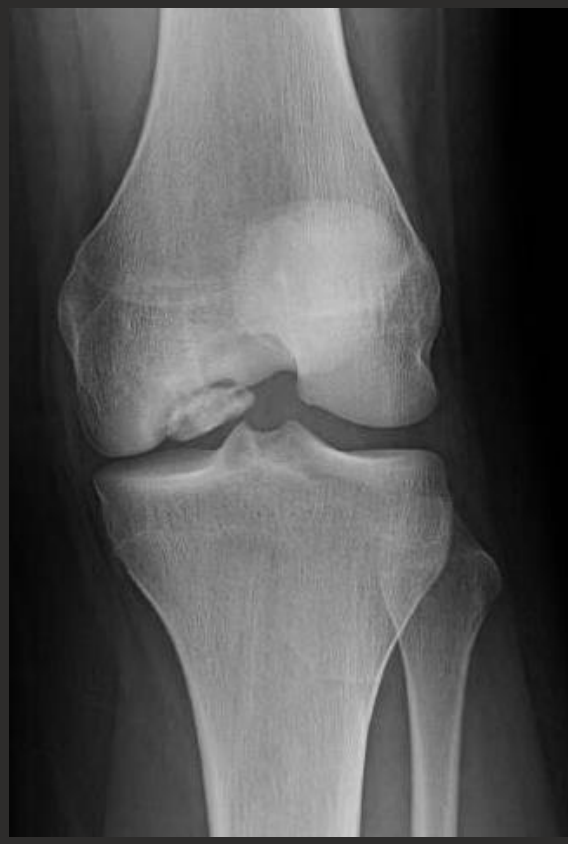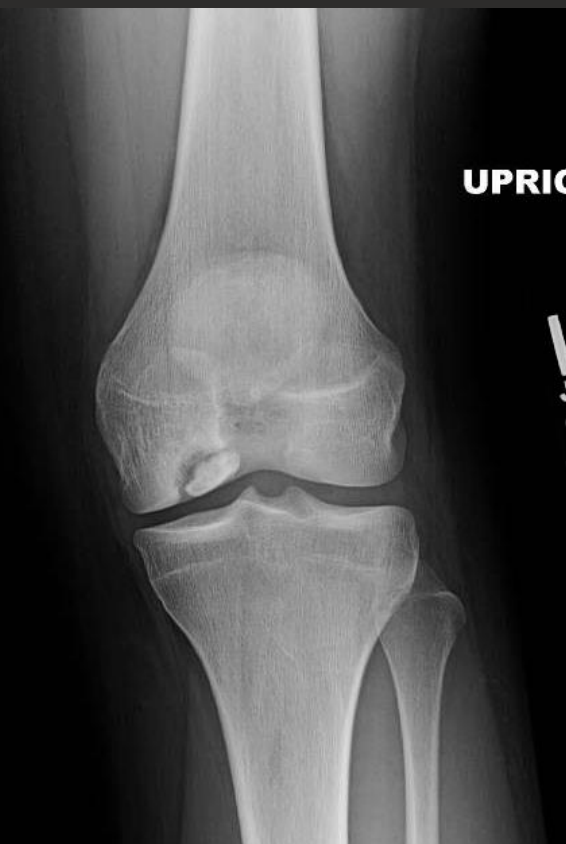History

- **December 2018 – Left Knee Arthroscopy with In-Situ Fixation of OCD with biocompression screws**

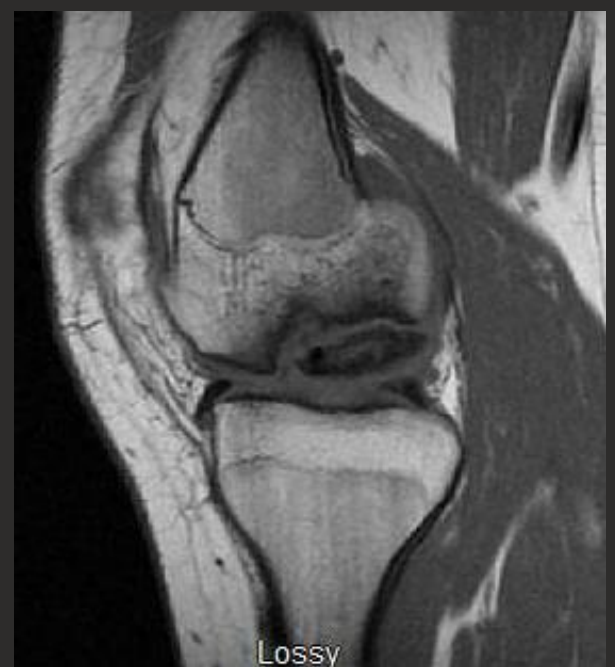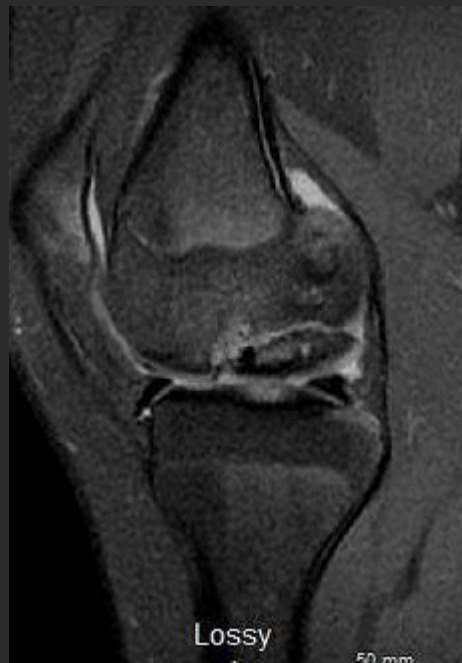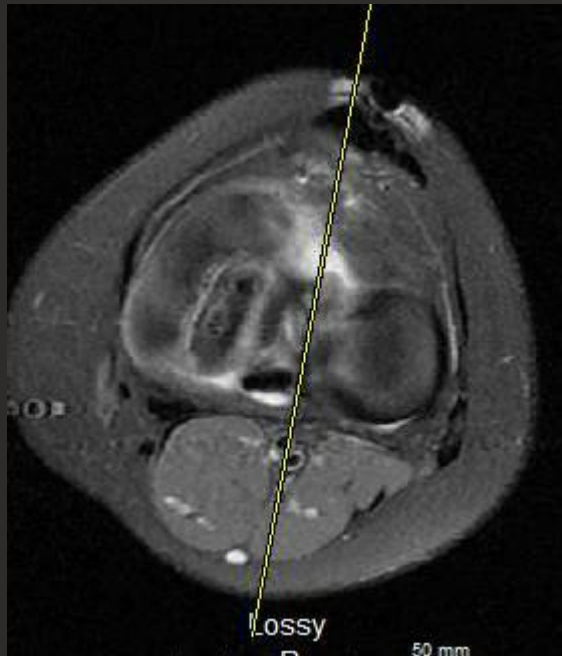
2/14/19 (3 months PO)



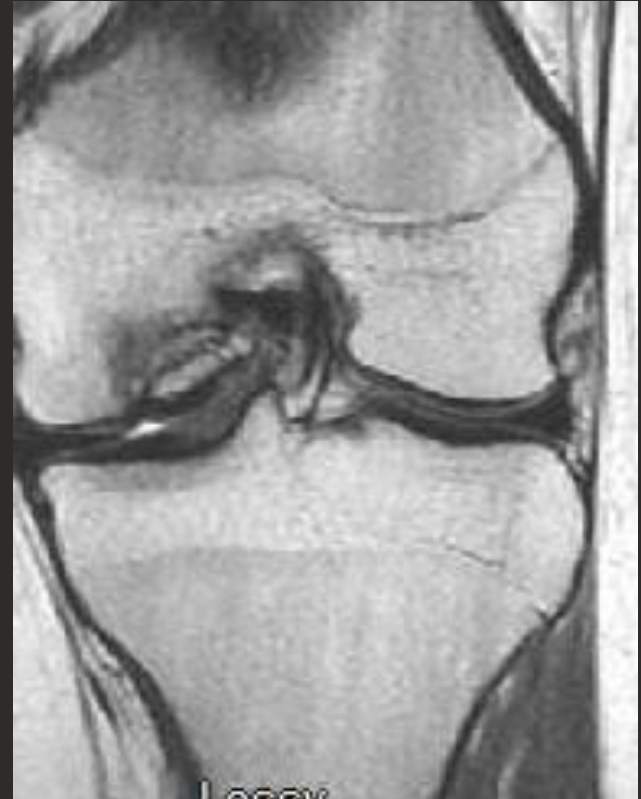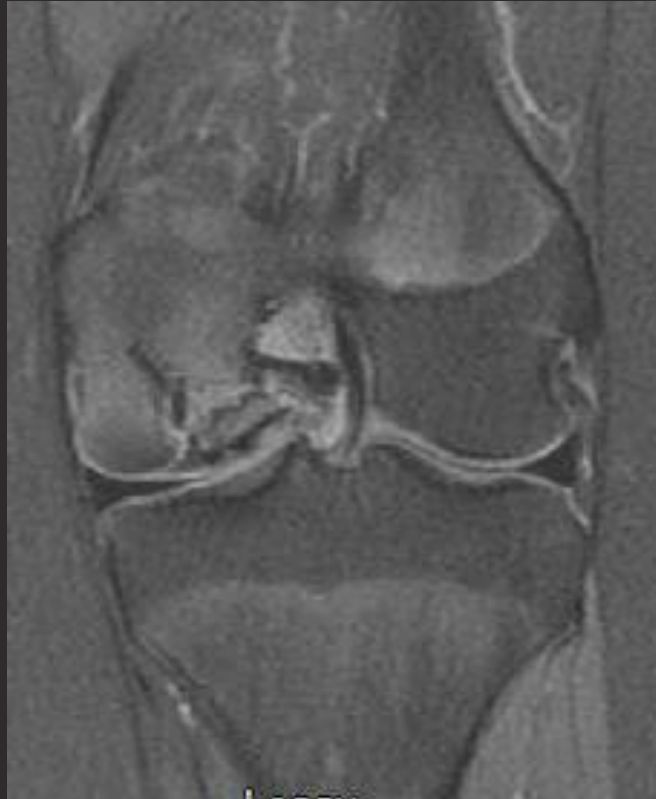5/28/19 (6 months PO)



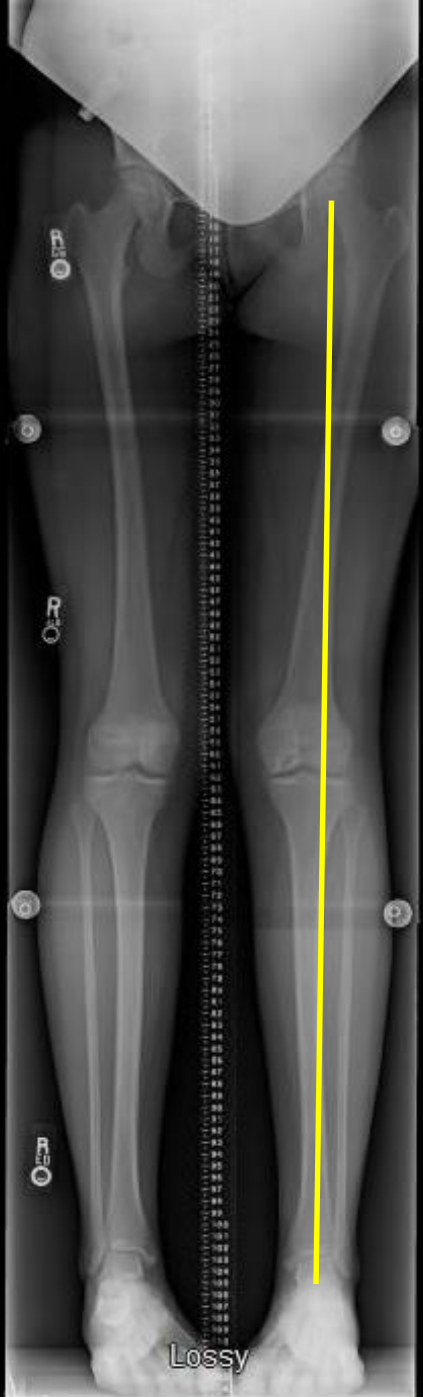
6/10/19



6/10/19



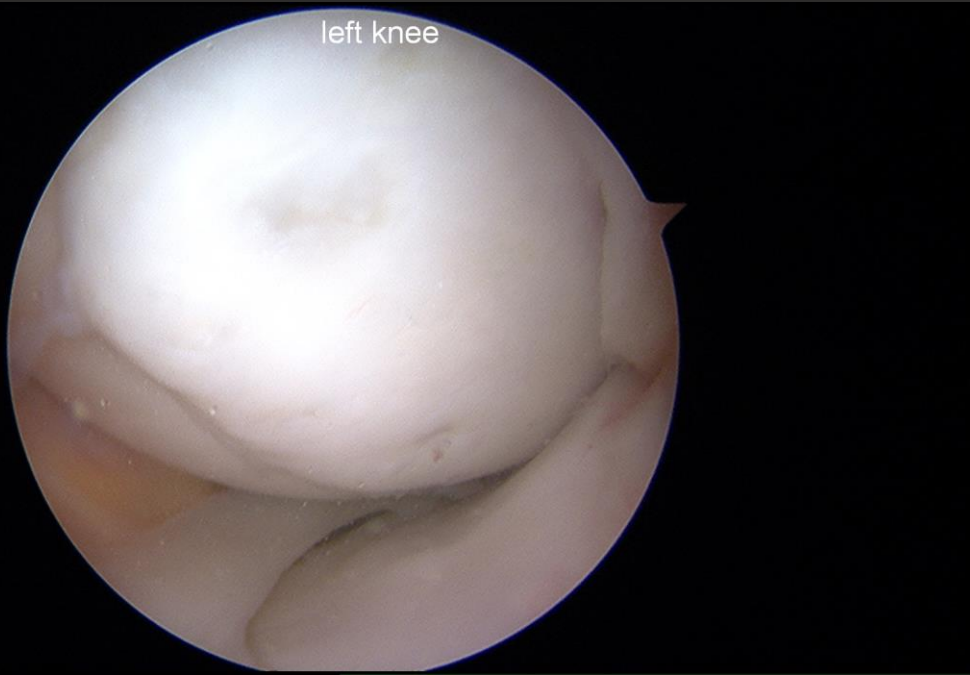
6/18/19



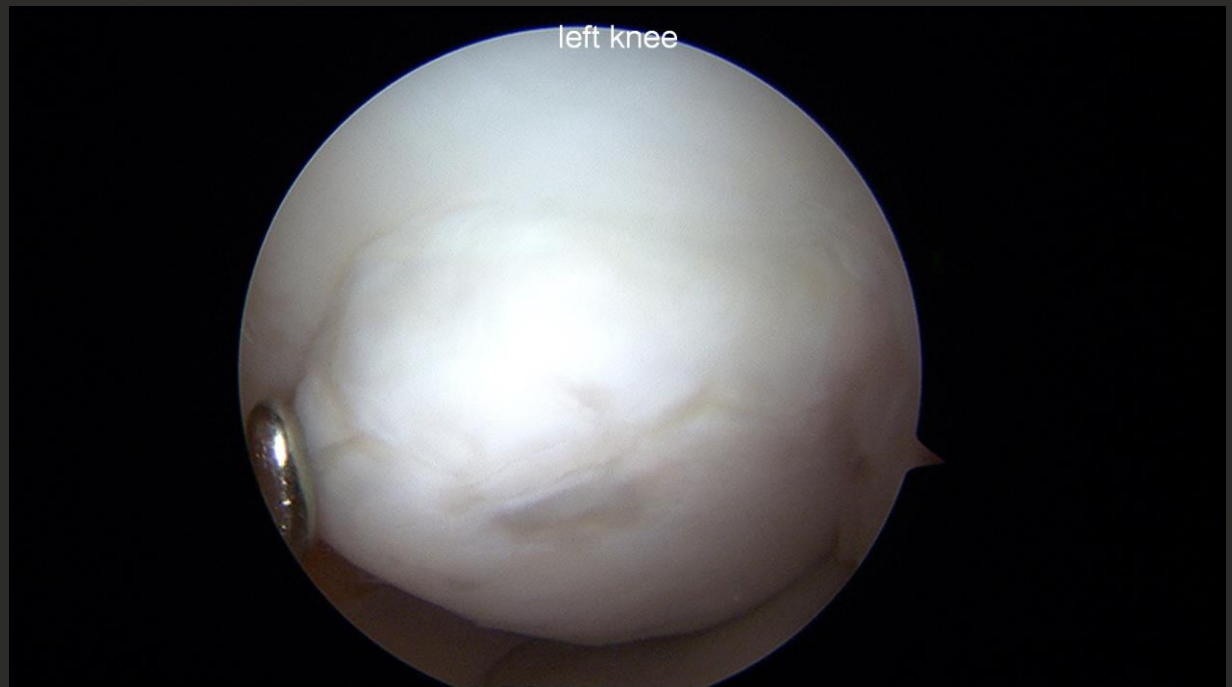History

- **Remains symptomatic and functionally limited**
- **Referred in for evaluation and treatment**

left knee

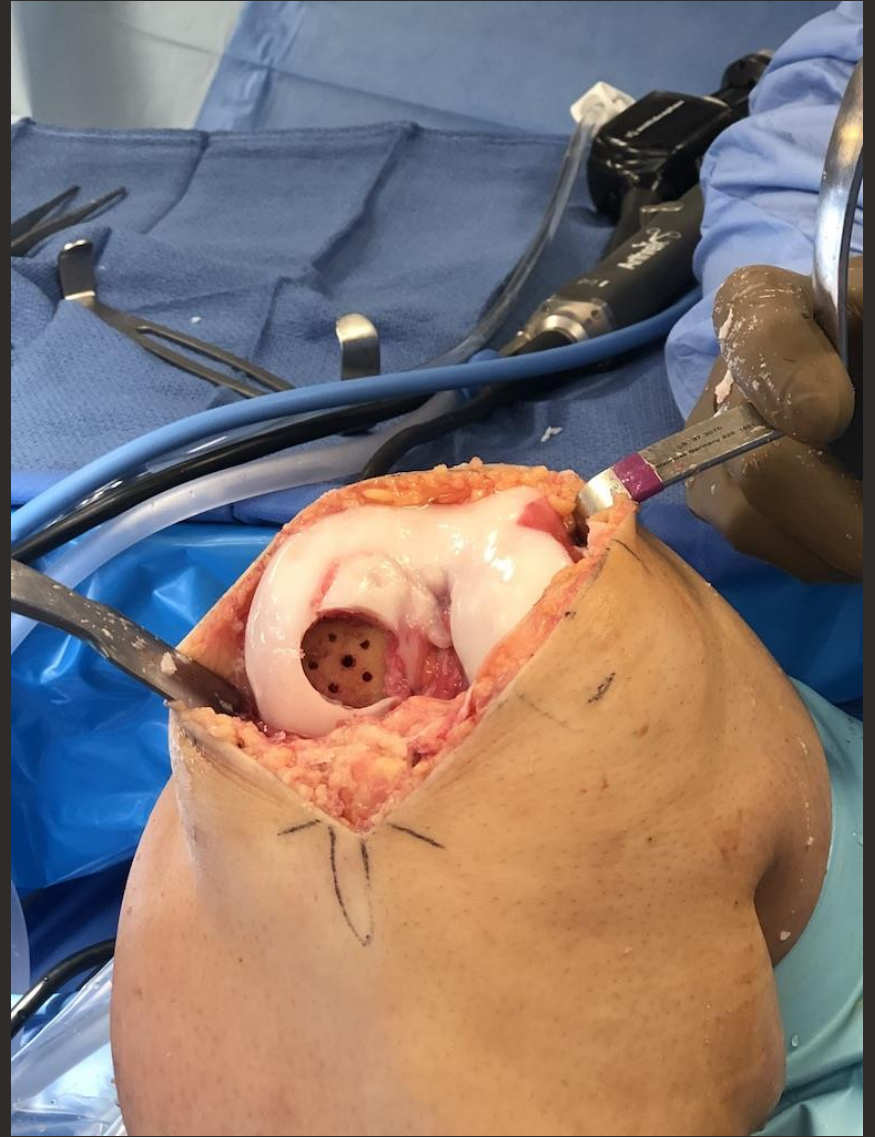
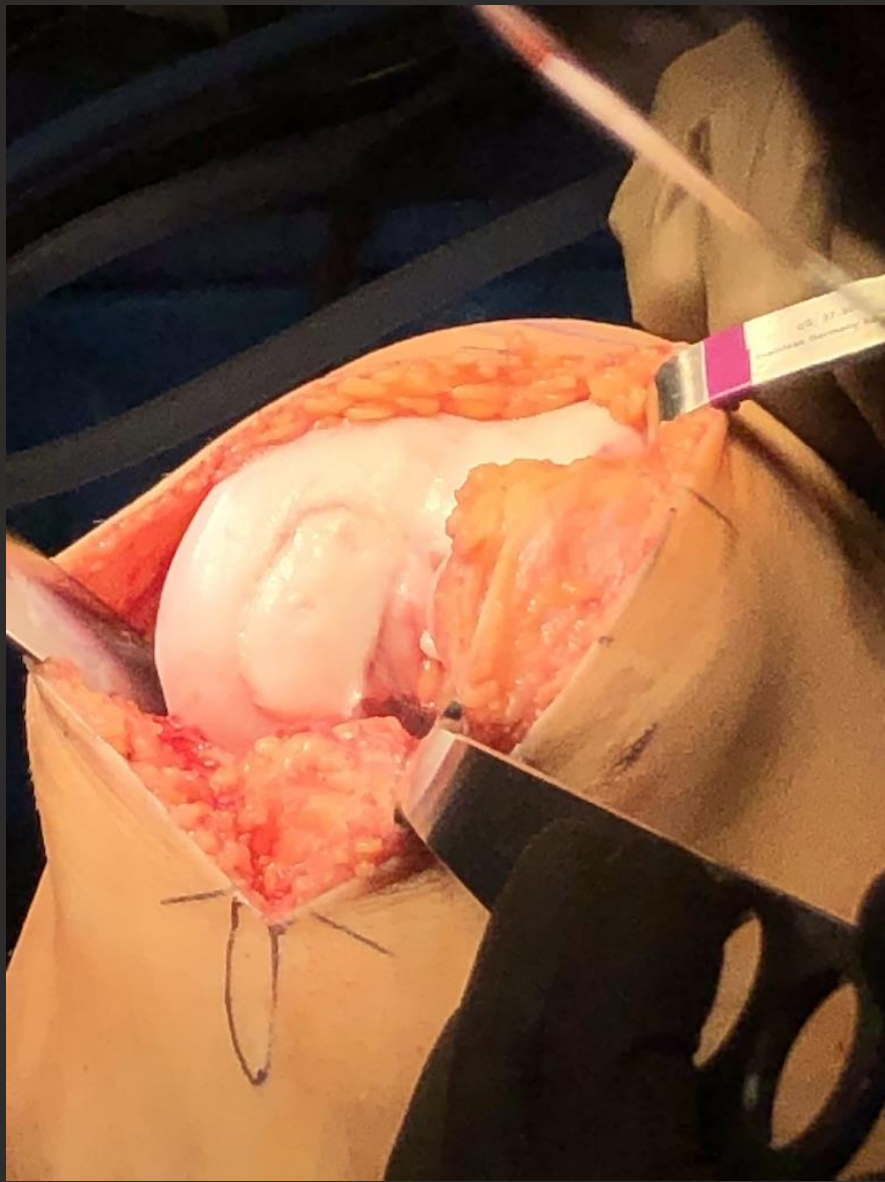

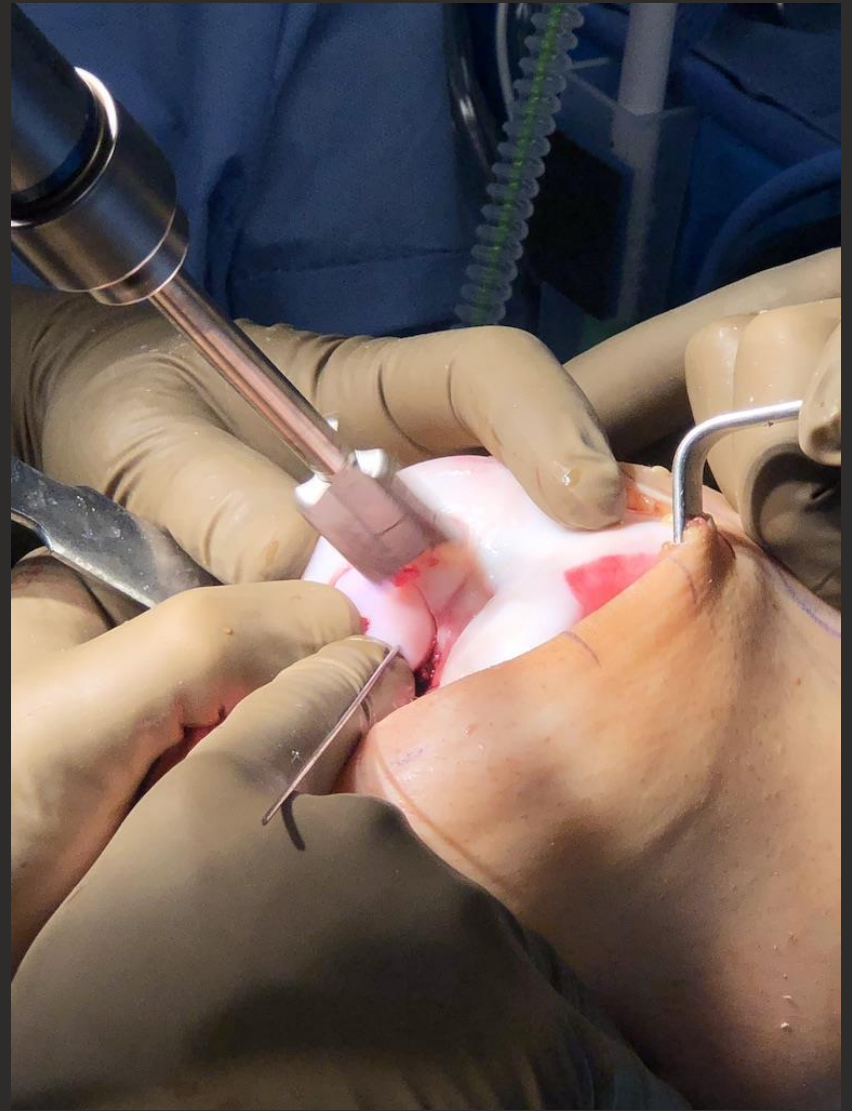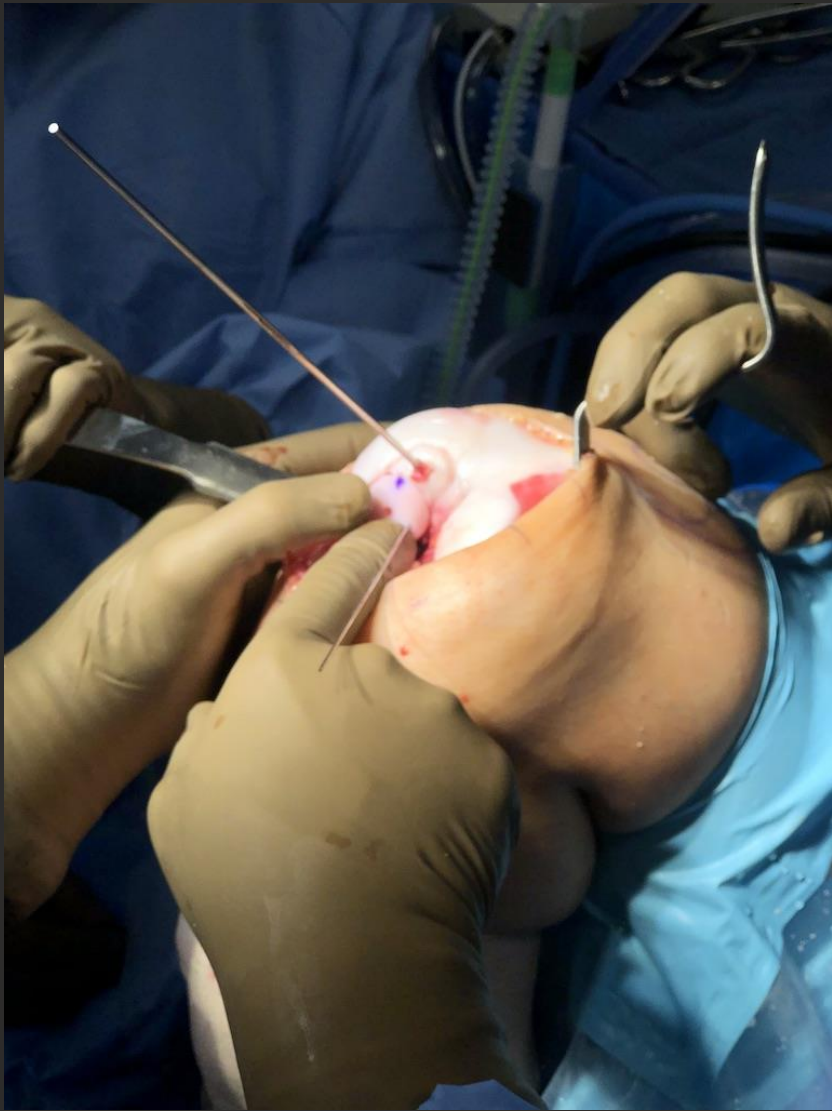left knee

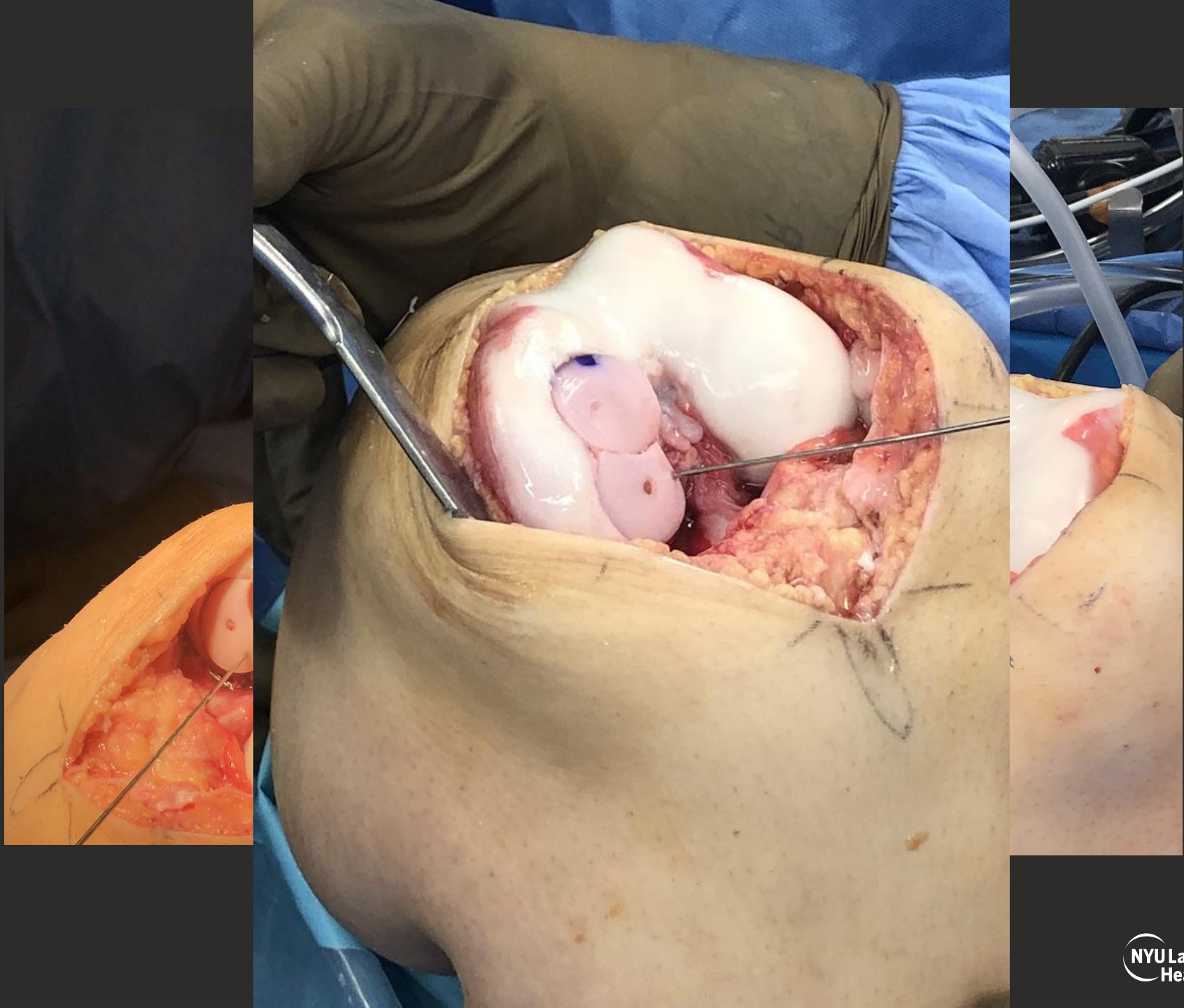


Questions?

- **What would you have done differently with respect to initial treatment?**
- **Are there any indications for second attempt at ORIF?**
- **OCA**
 - **Snowman vs BioUni?**
 - **How deep do you ream?**
 - **Bone graft?**
 - **Soak plug → BMAC/PRP**
 - **Compression screws?**









THANK YOU

